

# **Clinical and Scientific Validation for Optimizing the Neuromuscular Trajectory using the Chan Protocol**

**Clayton A. Chan, D.D.S., M.I.C.C.M.O**  
**Norman R. Thomas, B.D.S., B.Sc., Ph.D., M.I.C.C.M.O.**  
July 21, 2004

*“The main thing is to keep the main thing the main thing.”*  
*-Unknown*

## **Abstract:**

*Although there have been many clinicians that have clearly recognized a more anterior position, anterior to the classic pulsed neuromuscular trajectory and have treated forward of the pulsed trajectory with excellent clinical treatment results, none thus far have specified a clinical and repeatable technique to identify this anterior more optimized trajectory along with confirmed tomography of the condyles within the glenoid fossa. This paper considers the Chan Scan in the sagittal domain to identify an optimized neuromuscular trajectory and the anterior border of that physiologic zone. Observable effects of anteriorizing the mandible in the frontal/lateral domain has also been considered using computerized mandibular scanning confirmed with simultaneous EMGs with ultra low frequency Myomonitor TENS <20>. Tomographic evidence is used to confirm an optimized condylar disc relationship along the optimized neuromuscular trajectory. A clinical comparative study of the classic Scan 4/5 versus the optimized (Chan Scan) was done comprising 73 candidates (43 males, 31 females). Results indicated that 78.5% of all optimized (Chan Scan) trajectories taken were anterior to the classic scan 4/5 trajectory. 21.5% of the optimized (Chan Scan) trajectories were equal to the classic scan 4/5 trajectory. Patient's response to the modified scan was greatly improved over a shorter treatment period than the controls.*

## **Introduction**

Relating the human mandible to the cranium physiologically has been one of the complex challenges to many due to the wide range of mandibular movements that the widely separated two joint temporomandibular craniomandibular system can make with their associated musculature and ligamentous attachments.

Biomechanical models have been published to support the joint loading theory (Hylander, 1975; smith, 1978; Walker, 1978) and against joint loading (Robinson, 1946; Davis, 1955; Turnbull, 1970; Gingerich, 1971). It must be noted that only recently (Hylander, 1979; Brehnan et al., 1981) have developed techniques to measure joint loading supporting the idea that the loading occurs only during biting.

Jankelson (1984) distinguished between an adaptive (habitual) and true rest position of the mandible. He described the habitual (adaptive or accommodative) rest position as a pseudo rest position of the mandible that results from proprioceptive

conditioning of the central nervous system to position of the mandible within striking distance of habitual occlusion. <1> Using the Myo-monitor and kinesiograph, Konchak and Thomas et al (1987), in a study of 25 subjects helped clarify the difference between adaptive rest position (habitual or accommodative) and true rest position (physiologic rest position). <2>

Several early investigators as Perry (1957),<3>, Shpuntoff and Shpuntoff (1956) <4>, and Jarabak (1956) <5> used electromyography to identify rest position. Konchak and Thomas, et al (1988) in a study of 62 asymptomatic patients, monitored anterior temporalis and masseter muscles while recording the mandibular position with the mandibular kinesiograph. <6>

Wessberg, Epker and Ellito (1983), distinguished between three rest positions: clinical rest as induced by swallowing and phonetic functions, physiologic rest as induced by TENS, and physiologic rest as defined by minimal EMG activity. The authors concluded that physiologic rest position of the mandible can be induced reproducibly by either TENS or minimum integrated masticatory activity. <7>

The mandibular “neuromuscular trajectory” has been of special interest among clinicians using computerized diagnostic instrumentation. It is defined as the antero-posterior (AP) dimension along the isotonic path of mandibular closure from physiologic rest, the neuromuscular trajectory, where myocentric is to be established to begin a physiologic diagnosis and occlusal treatment.<8>

Studies comparing the habitual trajectory of a physiologic (normal) population to their myo-trajectory concluded that the two trajectories were coincident in a large percentage of the normal population. However, Cooper’s 1997 classic study on 1182 TMD patients who received successful treatment concluded that:

*"A total of 19.8% of patients had natural occlusion on the neuromuscular trajectory". For patients who received successful orthotic treatment "there was significant improvement in coincidence of occlusion on the neuromuscular trajectory (67%). At the test of the long term occlusal position, 93.4% of [treated] patients were on the neuromuscular trajectory". <9>*

Schneider and Wade, (1996), Wolford, and Jankelson, have observed and reported low EMG recordings anterior of the identified neuromuscular trajectory.

Jennings (1992), used speech patterns as an adjunctive diagnostic and prognostic tool to assess a craniomandibular relationship. No more than a 1.5 mm anterior/posterior or vertical shift between centric occlusion [habitual] trajectory and the [speech] trajectory for “S” words (Mississippi, San Francisco, Cincinnati, etc.) was reported. <22>

Computerized mandibular scanning studies indicated that speech patterns displayed varied sagittal anterior to posterior trajectories depending on whether the engrammed

mandibular position was referenced to either the habitual centric occlusion or referenced to the neuromuscular trajectory. <23>

It is this antero-posterior dimension as well as the fronto-lateral dimension that has challenged the clinician when trying to establish a finishing occlusal position of the mandible that identifies a neuromuscular trajectory after 45-60 minutes of myomonitor TENS. Mandibular changes have been observed with repeated follow up adjustment visits and confirmed with computer aided computerized jaw tracking instrumentation over time. The neuromuscular trajectory has also been noted to change over time in a more anterior direction due to physiologic healing of the masticatory musculature and temporomandibular joint decompression of discal tissues.

### Focus of This Paper

Dubrul (1980) described the ways in which the temporomandibular ligaments might in isolation constrain jaw movements. Baragar and Osborn in 1984 proposed a mathematical model relating patterns of human jaw movements to biomechanical constraints in which the articular eminences, temporomandibular and sphenomandibular ligaments along with their bony attachments influence movements of the human mandible. This model analyzed and predicted translatory and rotary condylar movements during jaw opening. <10,11,12> As the jaw is opened the equations indicated that the TM constraints line rises, reducing the size of the triangulated area occupied by the condyle center which is moved forward. At maximum gape the triangle reduces to a point thereby limiting the available positions of the center of the condyle to that point. Similarly, the incisor point must also be so confined as the condyle moves anteriorly.

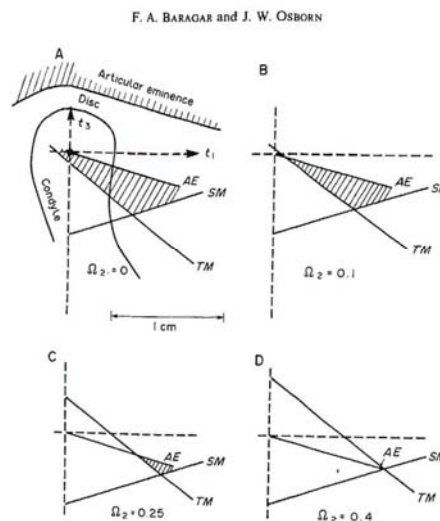


Figure 1: Baragar FA, Osborn JW: A model relating patterns of human jaw movements to biomechanical constraints. *J Biomech.* 1984;17(10):757-67.

With further study Osborn reported in 1993 a mechanical explanation for the observed movements of the condyle consistent with the principles that accessory ligaments have evolved around joints to reduce the need for some neuromuscular controls by replacing them with mechanical controls.<11> Furthering his studies he described the mechanics of jaw opening and the associated movement of the disc in a healthy human temporomandibular joint to explain the abnormal movements associated with internal derangement of the joint. He noted the biomechanical constraints on jaw opening imposed by the accessory ligaments around the jaw accounting for clicks on opening and closing, disc displacement and replacement, and conditions of opening and closed lock.<12>

Yatabe, Zwijnenburg, Megens and, Jaeije reported (1997) that the opening path of the kinematic center of the condylar movement lies above the closing path and thus closer to the articular eminence.<13>

### **Joint Anatomy and Their Ligamentous Constraints**

Osborn (1989) indicated that a body subjected to constraints does not necessarily move in the direction of an applied force. The capsular ligament of the Temporomandibular (TM) ligament is the only ligament actually in the joint. It is located on the anterior part of the lateral aspect of the joint. This ligament arises from the zygomatic process and articular eminence of the temporal bone and runs down posteriorly and inserts into an area just below the lateral pole of the condylar head and posterior neck of the condyle. It passes from the center of the articular tubercle to the posterolateral aspect of the neck of the condyle.

The temporomandibular ligament fibers are loose and would not constrain movements of the condyle except, perhaps, when they had been fully stretched at the limit of jaw opening. The Stylomandibular ligament is a slight thickening of the deep part of the parotid fascia and unlikely to constrain jaw movements (Last, 1956). The Sphenomandibular (SM) links the spine of the sphenoid and the lingula of the mandible. It limits joint decompression and protrusion. Osborn's mathematical model suggests the SM ligament behaves in a manner very similar to the TM ligament. The SM ligament probably remains slack until the jaw is widely opened, when it becomes taut and prevents any further jaw opening (DuBrul, 1980; Barager & Osborn, 1984).

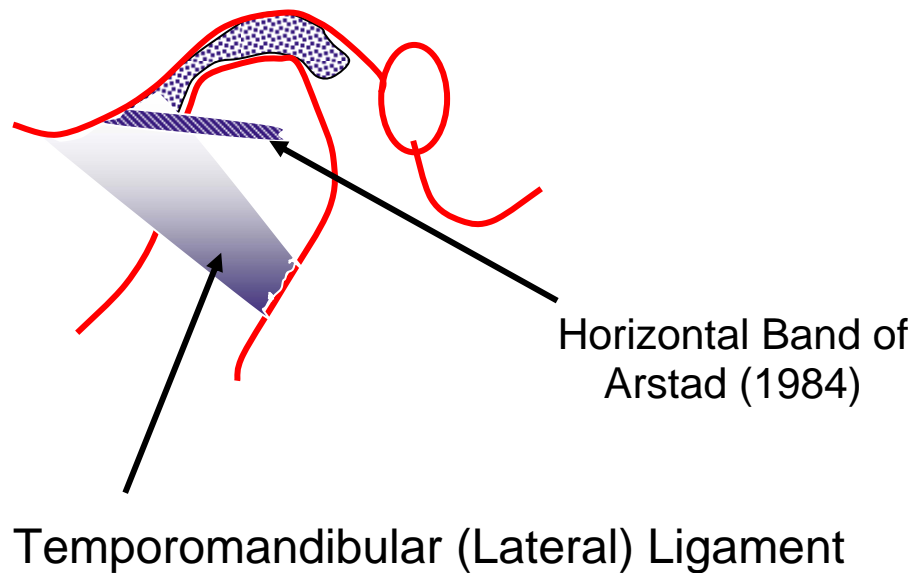
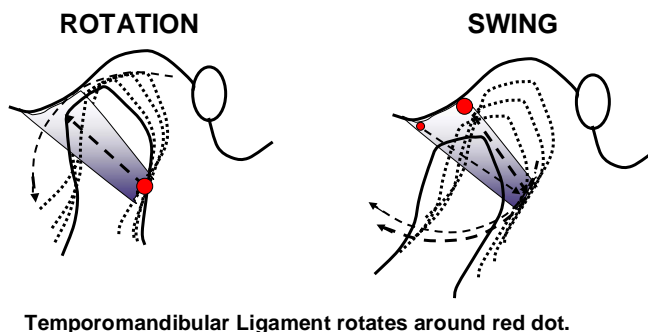


Figure 2: Function of the Temporomandibular Ligament: Keeps the condyle close to the temporal bone during jaw opening, until the condyle passes under the articular eminence.

### Condylar Rotation and Swing

In a mathematical sense the result of mandibular condylar movement was described as a combination of two movements; translation and rotation about some point in the plane. Rotation occurred some where at the posterior ligaments inserts into an area just below the lateral pole of the condylar head and posterior neck of the condyle. Translation or swing occurred at the broad ligament insertion at the zygomatic process allowing for swing and rotational changes to occur according to the position of the condyle and length of the ligament. Rotation and swing is a description that relates only a starting position and a finishing position of movement, but does not further indicate neither identifies the movements that have occurred between (Osborn). Grant (1973) also calculated a series of successive rotations of the mandible which changed continuously... not always limited in the condyle (axis), but shifted into the ramus of the mandible (Chen 1998; Grant 1973; Koolstra and van Eijden 1997). "It is clear, therefore, that the human TM joint is not a ball and socket joint which constrains the condyle to rotate about its center" (Rees, 1954; Osborn, 1985). The combination of swing and rotation used during jaw opening depends on the constraints caused by the shapes of the joints and TM ligaments, not the direction of the resultant of the muscle forces acting on the mandible (see Figure 3). When rotation and translation are simultaneously combined during jaw opening it is initially situated behind and below the condyle. (See figure 1 ,Barager & Osborn, 1984).

## Condylar Rotation and Swing



---

Figure 3: With a broad ligament the center for swing and rotation change according to the position of the condyle.

It must not be forgotten that during opening, the mandible is acted on by four combined forces. 1) the lateral pterygoid muscle which assists in antero-lateral movement of the condyle, 2) gravity which pulls the mandible downward, 3) the visco-elastic resistance to stretching jaw closing muscles, and 4) the anterior belly of the digastric muscles which allow for vertical posteriorizing of the mandible. The lateral pterygoid is comprised of both the superior head which arises from the greater wing of the sphenoid bone and the inferior head which arises from the lateral surface of the lateral pterygoid plate of the sphenoid bone. Both heads insert posteriorly on the neck of the condyle of the mandible with superior head attachments extending both in the condyle and articular disc.

Hiraba studies described the onset and offset firing of the superior (SUP) and inferior head (INF) of the LTP muscles during jaw opening (Figure 4). As the habitual opening cycle occurred stereotaxic EMG activity of the superior head of the lateral pterygoid (SUP) muscle displayed strong activity only in the closing phase, but no activity in the opening phase. SUP displayed quieter in the protrusive position. (Note protrusive was less than 3-5 mm change).

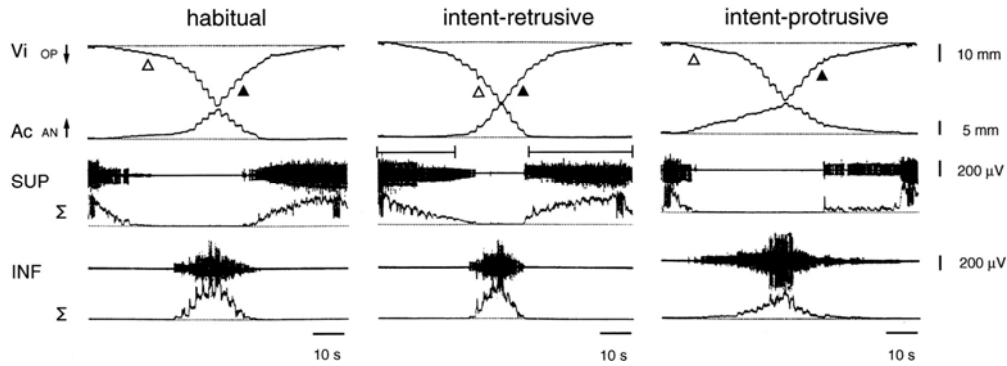


Figure 4: Onset and offset firing of the Superior and Inferior Head of the LTP as the jaw opens and closes.

It was also noted that as the SUP displayed no EMG activity in opening phases, there was also inferior head of the lateral pterygoid EMG activity during opening simultaneous, even during the protrusive phase.

Hiraba's findings indicated 1) that as the mandible opens the SUP switches off, 2) As it closes it switches on, 3) SUP is switched on during rotation of the mandible, 4) On protrusion/translation SUP switches off and 5) Stretch reflex-like response in the SUP shows high EMG amplitude coincident with posterior superior displacement of the condyle during passive retrusion. See figure 5.

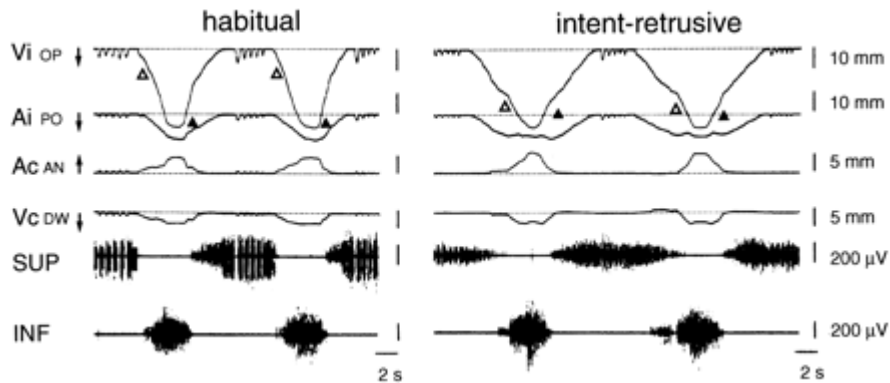


Figure 5: Jaw movements and EMG activities during habitual, intent retrusive opening and closing (Fig 7) of Hiraba studies.

This suggests that the SUP does not work to change Ac, but acts to regulate the angular relationship between the condyle and disk within its working range between 0 to 3-5 mm Ac.

It can be reasonably be concluded that functional significance of the SUP for the condylar movement is to control the relative positional relationship between the disc

and condyle, whereas the position of the disc in relation to the maxilla is controlled indirectly by the INF because of the disc is attached to the condyle by tendinous ligaments (Rees 1954; Schmolke 1994; Wilkinson 1989).

### **New Discoveries and Advances in the Use of sEMG and CMS**

In the past years, new discoveries and advances have been made combining the simultaneous monitoring of surface electromyography (sEMG) and the use of computerized mandibular scanning (CMS). Having the capability to visualize both EMG and CMS synchronously after ultra-low frequency TENS and during TENS in real time has enhanced the clinicians awareness of masticatory activity with mandibular positioning optimally using tomography to confirm condylar positioning. The clinician is better able to correlate muscle activity with the corresponding mandibular habitual trajectory (before TENS) and the “classic” neuromuscular trajectory (after TENS). With further studies a technique has been devised to optimize the physiologic antero-posterior (Chan Scan) trajectory and resting zone of masticatory muscle activity optimally both in the antero-posterior, vertical as well as the lateral/frontal domains before taking a myocentric bite registration objectively. This technique takes into consideration the auxillary ligamentous constraints of jaw motion, the limits of mandibular freedom and the findings of Baragar and Osborn’s mathematical model of jaw motion in three dimensions.

Luschei as well as Kaas noted the effects of engramming muscles patterns to mandibular movement. Luschei indicated, *“Routine movements of the mandible are the result of a learned engramming of the “motor memory” at birth. These learned movements can change due to an increase in normal recognized motor ability occurances. They can also change by compensating for injury or disease states which influence behavioral modification in mandibular occluding movements. Any change in the normal engrammed patterned state, due to developing occlusal interferences, change in occlusal morphology, injury or disease that alters a normal engrammed pattern of movement will cause a new avoidance pattern to develop to avoid further injury.”* <24, 25>

This author proposes based on the scientific literature that a neuro-ligamento-muscular connection does affect the neuromuscular trajectory as they relate to the lateral pterygoid complex and digastric/suprahoid muscle groups. The neuromuscular trajectory is determined by muscles, but ligamentously controlled when muscles are fully relaxed.

### **Lateral Pterygoid and Low Frequency TENS**

Research indicates that when pulsing the nerve, both the superior and inferior heads function synchronously which is “un-physiologic” (as it relates to the trajectory). TENS stimulates the superior and inferior head of LP’s in synch. **THIS IS NOT PHYSIOLOGIC.** By advancing the mandible (Chan Scan) studies show there is a balancing out effect of the upper and lower heads to derive a more physiologic position.<26> The superior head is switched off when PROTRUDING the mandible forward. By advancing the mandible there is an inhibitory involuntary contraction of



the superior head of the LP muscle. The inferior head as it is brought forward (Chan Scan) is being activated while the superior is being inactivated at the proper physiologic balance.

Chan, et. al. has also shown numerous times that when pulsing with TENS the “neuromuscular trajectory” is not always a parallel trajectory with the habitual trajectory even when starting from a rested position. With TENS the disc can come forward, which shouldn’t occur. By advancing the mandible (Chan Scan) the SUP switches off (Hiraba, et al., see Figure 5). When opening the jaw (protruding) you switch off the superior head.

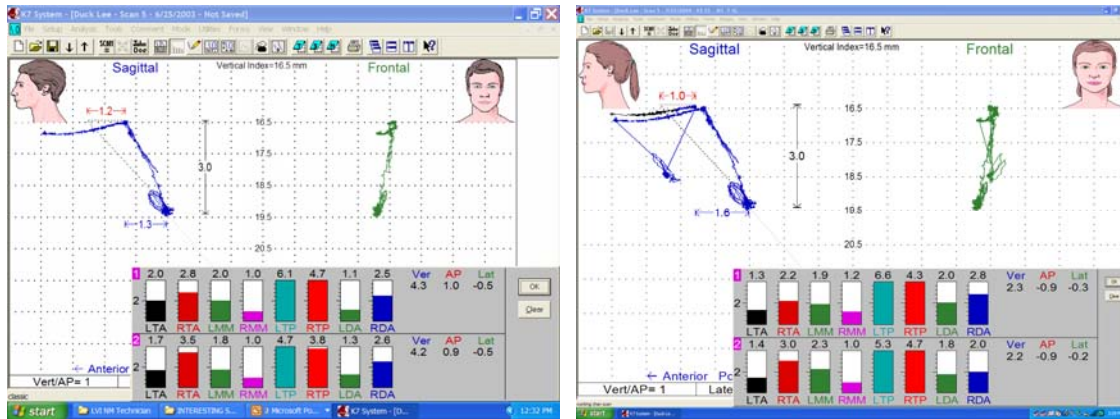
### **Which Trajectory is the Correct Neuromuscular Trajectory?**

Trying to establish a physiologically proper antero-posterior mandibular relationship to the maxillary arch has been one of the most challenging of all three dimensions (sagittal/antero-posterior, vertical, frontal/lateral) for the treating dental clinician. It is one of the more critical of all dimensions and the least forgiving, especially when it comes to occlusal management<1>.

It is known that the myomonitor TENS pulse will produce a neuromuscular trajectory via involuntary muscle stimulation (Jankelson). It has also been recognized that after 45-60 minutes of ultra low frequency TENS motor point stimulation that a physiologic rest position is evoked.<14>

Having observed that a deficient posterior occlusal support is accompanied by superior and posterior positioning of the condyle in the glenoid fossa it was further noted on tomography that TENS induces condylar decompression in a down and forward direction. As condylar decompression takes place there is a concomitant change in opening and closing mandibular path (neuromuscular trajectory) from the habitual engrammed closure pattern to what has been termed the myomonitor pulsed neuromuscular trajectory typically anterior to the habitual trajectory.<14>

Based on objective data the clinician has typically taken a myocentric bite registration along the neuromuscular trajectory that lies anterior to the habitual trajectory. It was therefore decided to pursue an even more optimal trajectory utilizing EMG and CMS data.



Stage I - Classic Trajectory

Stage II - Chan Scan Trajectory

Figure 6: The right scan 5 shows an anteriorized trajectory forward of the classic trajectory (triangulated position). As the mandible is anteriorized the temporalis anterior muscle group decreases.

### STAGE II – Modified Scan 5 (Chan Scan)

The rationale is to identify a more optimal trajectory based on a reduction in EMG readings (anterior temporalis, masseter, digastric/suprahyoid and posterior temporalis/cervical) while carefully monitoring sagittal and frontal cursor CMS positions. As the patient allows the mandible to float downwards from a position anterior to the neuromuscular trajectory it is noted that it stabilizes at low EMG values during myomonitor TENS stimulation. The patient is repeatedly required to allow the mandible to relax downward from its forward position where it takes up a constant downward and forward trajectory at the most reduced EMG levels. <15>

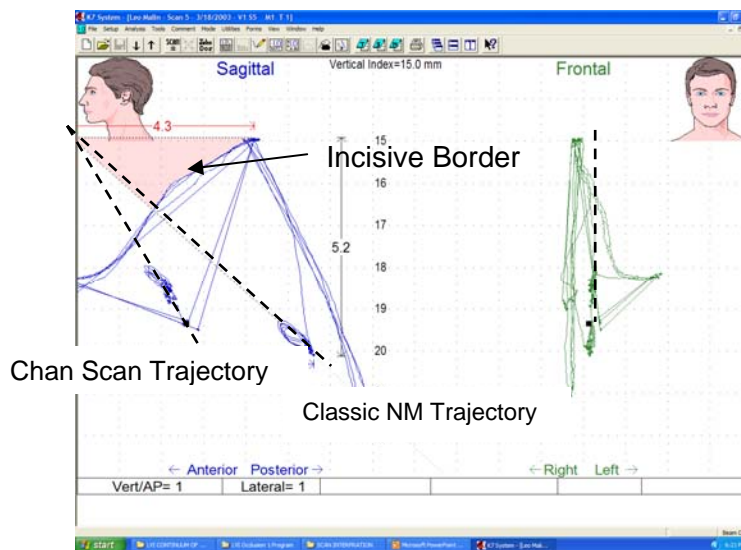


Figure 7: Compared with Osborn's diagram and anatomical constraints the following observations have been made; a) the triangle below the incisive border becomes

smaller as the mandible anteriorizes, b) the triangulated area above the incisive border increases as the mandible anteriorizes, and c) the neuromuscular trajectory becomes more parallel to habitual trajectory as the mandible anteriorizes.

### **OBSERVED FEATURES OF THE CHAN SCAN:**

- Optimized the AP Trajectory confirmed with EMGs.
- Optimized low temporalis anterior muscle activity
- Condylar disc re-positioning (*reducing the disc*) frontally and sagittally.
- Repeated sagittal cursor position after the protrusive movement with respect to the displayed NM Trajectory (tagged/marked).
- Confirmation of a more optimal AP Trajectory with repeated cursor positioning and resting EMGs
- Confirming of a more optimal physiologic rest zone with repeated cursor positioning and resting EMGs.
- Quantifying more accurately in millimeters how much would have to be ground on the sagittal plane to accommodate closure to C.O. (pink triangle).

### **Correlating Condylar Positioning with the Chan Scan Trajectory**

Condylar/disc relationships have been known to change over time<sup><16,17,18></sup> with a tendency toward a posterior superior relationship within the glenoid fossa when deficient posterior occlusion exists, thus TM joint compression. When the masticatory muscles are relaxed the mandible/condyle/disc relationship changes relative to the cranial base resulting in joint decompression in a down and forward position, allowing a more anterior trajectory relative to the existing habitual trajectory.

Many studies have demonstrated condyle positioning in an inferior and anterior position are more optimal especially when treating patients with joint derangements, masticatory muscle dysfunction and when there is an existence of masticatory pain. Scientific studies have also indicated that retro-discal fibro-connective tissue fill in does occur over time<sup><16,17,18></sup>, thus preventing condyles from relapsing back in a posteriorized position within the glenoid fossae once musculoskeletal occlusal stability has occurred.

The optimized neuromuscular trajectory (Chan Scan) correlated with tomographic evidence indicates that the condyle is often anterior and inferior of the glenoid fossa (down and forward of the eminence) compared to the more traditional concepts of centered of the fossa temporomandibular joint teachings.

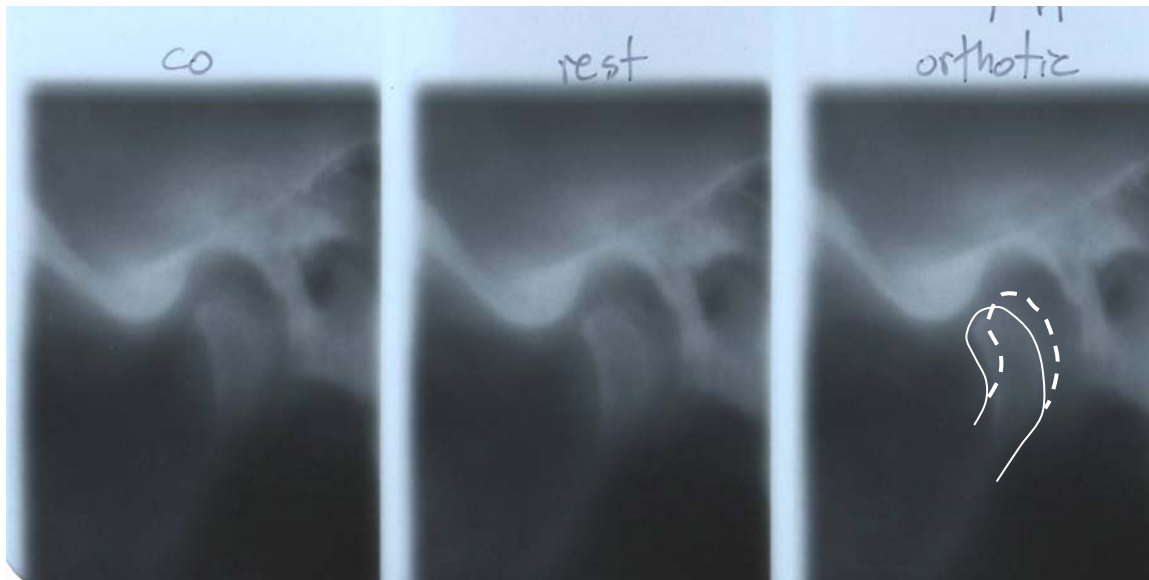


Figure 8: Tomogram taken at centric occlusion (CO), rest position, and Chan Scan Position (Optimized Neuromuscular Trajectory). The orthotic was positioned to capture the condyle to disc relationship. Dotted outline indicates potential condylar remodeled position.

Many clinicians have reported that the trajectory changes in a more anterior direction in those cases that are not musculoskeletal occlusally stable following TENS. A more anterior trajectory with accompanying low EMGs has been identified. As a result of such positive mandibular changes, modification to the occlusal surface of the orthotic appliance or the teeth maybe indicated to accommodate this change by rendering a coronoplasty adjustment or resurfacing of the orthosis appliance to accommodate for the musculoskeletal occlusal change.

#### Sagittal Cursor Positioning With the Chan Scan Technique

The author reports, that on scan 4/5 EMG bite recordings, there is a more anterior cursor position following mandibular protrusive movement on the sagittal CMS recording when the mandible was allowed to slowly relax and float to a resting end point (typically on the third to fifth repeated trial). Occasionally he observed the cursor to move back on to the displayed myomonitor TENS pulsed trajectory. At other times the cursor “floats” anterior to the myomonitor TENS trajectory. This leads to the reproducibility question and answers the concern of variable results seemingly observed by those skeptics that did not have an in depth understanding of muscle and joint physiology as well as less experience with the meaning of the active computerized electro-diagnostic data and refined cursor movement and positioning. These observations have further lead the clinician to locate a repeatable optimized myocentric bite position both sagittally and frontally after careful monitoring of a repositioned cursor, thus better addressing the clinicians concern of variable results on repeated scan 4/5 testing.

### Frontal/Lateral Cursor Positioning

The frontal/lateral cursor position using scan 4/5 has been observed noting a resting pulsed position slightly left or right of the habitual centric occlusion. With further investigation and testing it has been noted that the Chan Scan technique is better able to identify whether discal tissue is reduced/ recaptured bilaterally. As the patient is instructed to protrude and slowly relax the mandible the author has correlated the frontal scans with condylar/discal tissue positioning, resting muscle EMGs, as well as taking into account the ligamentous constraints as to the repeatability of the cursor positioning and its clinical significance as they pertain to joint reduction and disc recapturing. The correction is identified by the normalizing of the mandibular opening and closing path free of deviations.

### **Discussion**

The Chan Scan gives further insight into finding the clinical antero-posterior constraints individually as well as assisting the clinician to discover a repeatable trajectory based on mathematical and equatic models of mandibular movement (Baragar and Osborn). It is possible that when protruding the mandible forward, extending to a taut ligamentously constrained position, to the corner of the triangle indicated by Osborn, that the mandible is able to relax within the zone similar to the repeatable optimized Chan Scan trajectory that is confirmed by low EMG and CMS recordings (See Figure 8). The Chan Scan is not dependant on low EMG readings only, but takes into consideration ligamentous, muscle, bone, discal tissue and occlusal constraints that allows mandibular stabilization to occur in the antero-posterior, vertical, lateral as well as pitch, yaw and roll domains.

When pulsing with low frequency Myomonitor TENS, the neuromuscular trajectory is not always parallel with habitual trajectory when establishing a physiologic rest position. With low frequency Myomonitor TENS the articular disc comes forward. This should not occur independent of condylar advancement during TENS. TENS stimulates the superior and inferior head of LP's synchronously. This is not physiologic. By advancing the mandible in the Chan Scan you balance out the effect of the upper and lower heads to derive a more physiologic position. The superior head is switched off when PROTRUDING the mandible forward (Hiraba). The involuntary contraction of the superior head of the LP muscle is inhibited. By advancing the mandible (Chan Scan) a switching off the superior head of the lateral pterygoid EMG activity has been reported by Hiraba, et al, (2000). <21>

### **Combining the Scientific Literature with Clinical Trajectory Findings**

Osborn and Baragar have attempted to give a scientific mathematical model that takes into consideration the ligamenetous constraints of the temporomandibular ligament and sphenomandibular ligament as they relate to the rotation and swing of the condyle within the glenoid fossa. Hiraba, et. al, have scientifically recognized the SUP and INF muscle EMG activities role during opening/closing and protrusive jaw movements. With further investigation with Chan, Wade and Thomas that there are

trajectory angulation differences that can be a result from muscle and ligamentous constraint engrams that influence computerized mandibular (CMS) trajectory tracings on both the sagittal and frontal planes. The classical neuromuscular trajectory may not always be parallel to the habitual trajectory due to SUP and INF influences regardless of the duration of the TENS stimulus. When protruding the mandible forward of a classic diverging trajectory (away from the habitual trajectory) it has been recognized that EMG activity decreases in the temporalis anterior, masseter, cervical neck and digastric groups when monitoring EMG activity during CMS tests as long as the protrusive movement is within the ligamentous constraints of bordered movements. Forward of the classic trajectory can exhibit a more parallel neuromuscular trajectory to the habitual trajectory which has temporomandibular joint/eminence angulation significance as to determining an optimized mandibular and condylar position relative to the cranial base and glenoid fossa.

Areas of constraints have been mathematically derived by Osborn as to condylar movement within the constraints of the accompanying ligamentous attachments. A further extrapolation of the temporomandibular ligament constraints as they relate to various trajectory patterns (habitual, TENS trajectory and the Optimized Chan Trajectory) have been recognized to validate physiologic EMG and anatomical mandibular/condylar positioning parameters.

### **Correlating Condylar Triangulated Constraints with the Kinesographic Occlusal Triangle Constraints**

Using the Myotronics K7 Kinesographic Scan 4/5 and its capability to mathematically analyze in tenths of a square millimeter as to how much tooth structure may need to be occlusally adjusted (coronoplasty) prior to any occlusal treatment is of clinical significance in diagnosis and treatment. The K7 is able to calculate a triangulated area composed of the protrusive incisive border from CO, the neuromuscular trajectory, and the horizontal plane acting as the third border of a triangulated area that represents the discrepancy between a habitual trajectory and the neuromuscular trajectory mathematically calculated in tenths of a square millimeter area that would have to be ground (adjusted) to accommodate closure to a neuromuscular trajectory.

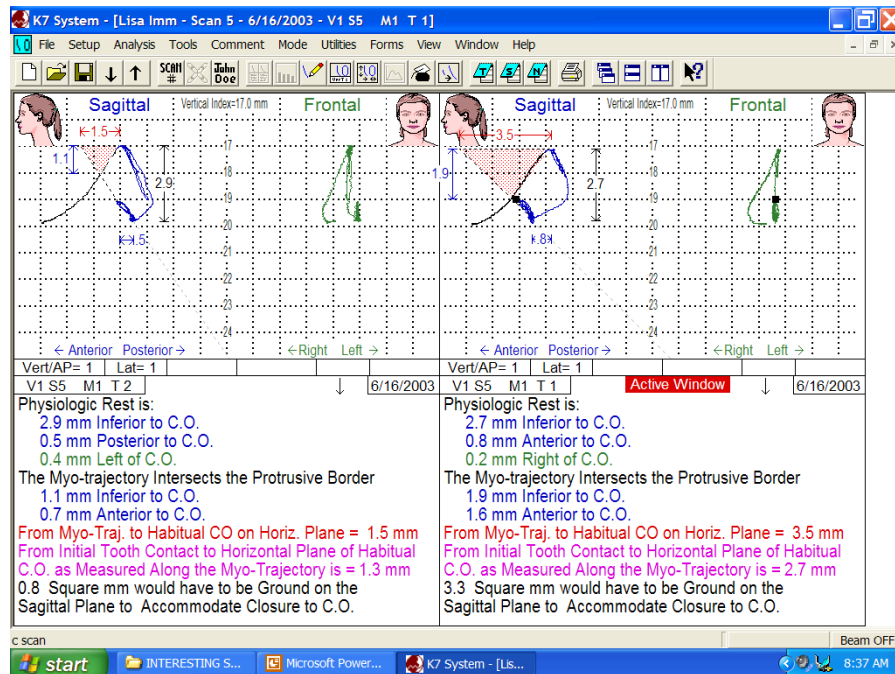


Figure 9: The pink triangle on the left represents the square millimeters that would have to be ground on the sagittal plane using a classic neuromuscular trajectory. The pink triangle on the right represents the square millimeters that would have to be ground on the sagittal plane when an optimized mandibular position is determined with the Chan Scan (Scan 4/5 Modified). The pink triangle can vary depending on which trajectory is determined resulting in varying values of square millimeters that would have to be ground on the sagittal plane to accommodate closure to C.O. (Myotronics K7 Kinesograph).

It is this area of the K7 triangle that can be correlated mathematically as to an optimized EMG/CMS guided bite registration within the mathematical ligamentous constraints of the condyle and lateral pterygoid muscle groups (see Figure 10).

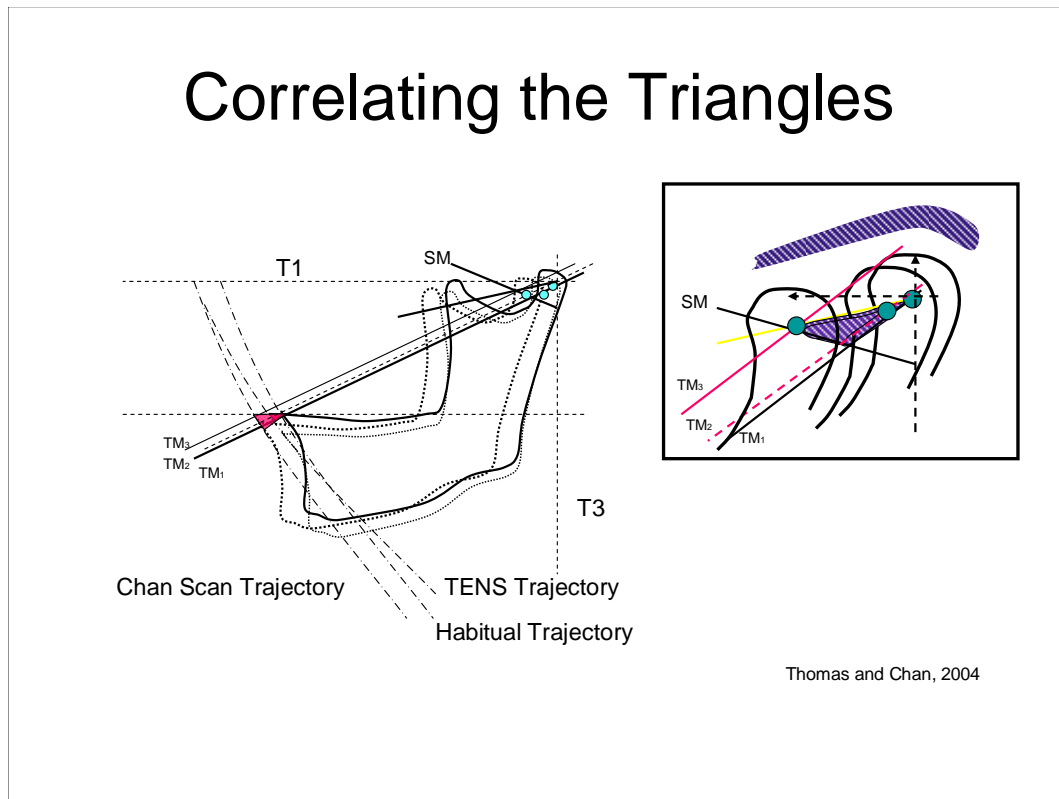


Figure 10: Osborn's ligamentous constraint triangles correlated with various trajectories and the Myotronics K7 (pink triangle) descriptive analysis as to how much would have to be ground on the sagittal plane to accommodate an optimal trajectory closure pattern (sagittal and frontal) to CO.

### Conclusion

Certainly within the bio-physiologic parameters there are zones of physiologic homeostasis, normalcy and aesthetic proportions, rather than specific points or specific positions.<19> A clinical comparative study of the classic Scan 4/5 versus the optimized (Chan Scan) was done in June 2003 and March 2004.<26> A combined candidate total for this study comprised 73 Candidates (43 males, 31 females). Results indicated that 78.5% of all optimized (Chan Scan) trajectories taken were anterior to the classic scan 4/5 trajectory. 21.5% of the optimized (Chan Scan) trajectories were equal to the classic scan 4/5 trajectory. All patients were improved and less subsequent appointments and orthotic resurfacings were required.

Finding and optimizing a neuromuscular trajectory using the Scan 4/5 Chan Scan technique must take into consideration all bio-physiologic laws of nature as well as the use of all the available tools such as: electromyographic optimization of resting EMG recordings with ultra low frequency TENS and confirmed with computerized mandibular scanning (CMS). It should also take into consideration the anatomical constraints of all tissue structures both hard and soft of the masticatory complex. Upper masticatory factors as well as lower cervical/neck and postural factors must also be considered when optimizing the neuromuscular trajectory with the Chan Scan



technique. This paper confirms the optimal use of not only EMG recordings before and after ultra low frequency TENS, but just as significantly important is the CMS recordings to confirm an optimized trajectory with low frequency TENS to validate scientifically EMG optimization and mandibular/condylar and occlusal positioning.

This paper serves as an introduction into a series of papers being prepared to cover such topics as:

1. Anatomy/physiology of the joint complex and associated muscles including the lateral pterygoid (upper/lower heads).
2. Anatomy/physiology of the associated ligaments and their role on the modified Scan 4/5.
3. Discovering the Chan Scan.
4. Background, history and the evolution of Scan 4/5 (Chan Scan).
5. A reproducible technique and protocols for clinical application.
6. Cursor movement and positioning as it relates to joint anatomy and positioning within the glenoid fossa.
7. Scan interpretation of the Chan Scan.
8. Biomechanical mathematical models supporting the optimized myocentric bite with the Chan Scan.

#### **Authors Note:**

The "Chan Scan" was identified and named by Bill Wade during a neuromuscular occlusion training program in 2003 to identify Dr. Chan's developed and discovered optimized Scan 4/5 technique while they both were instructing at the Las Vegas Institute. Bill exclaimed to the whole group of doctors, "Check out Chan's Scan!" Since that time it has been noted among the doctors as the Chan Scan.

#### **References:**

1. Jankelson B: *Three –dimensional Orthodontic Diagnosis and Treatment: A Neuromuscular Approach*, J Clin Orthod 1984; 18:9:627.
2. Konchak PA, Thomas NR, Lanigan DT and Devon R: *Vertical Dimension and Freeway Space: A Kinesiographic Study*, Angle Orthodont Apr 1987; 57:2:145-154.
3. Perry HT: *Muscular Changes Associated With Temporomandibular Joint Dysfunction*, J Am Dent Assoc 1957; 54:644-653.
4. Shpuntoff H and Shpuntoff W: *A Study of Physiologic Rest Position and Centric Position by Electromyography*, J Prosth Dent 1956; 6:5:621-628.
5. Jarabak JR: *An Electromyographic Analysis of Muscular and Temporomandibular Joint Disturbances Due to Imbalances in Occlusion*, Angle Orthodont 1956; 26:3:179-190.

6. Konchak PA, Thomas NR, Lanigan DT and Devon RM: Freeway Space Measurement Using Mandibular Kinesiograph and EMG Before and After TENS, *Angle Orthodont* 1988;343-350.
7. Wessberg GA, Epker BN and Elliot AC: *Comparison of Mandibular Rest Positions Induced by Phonetics, Transcutaneous Electrical Stimulation, and Masticatory Electromyography*, *J Prosth Dent* Jan 1983; 49:1:100-105.
8. Cooper B: *The role of bioelectrical instrumentation in the documentation Path oral Radiol and Management of temporomandibular disorders*. *Oral Surg Oral Med Oral Endod* 1997;83:91-100.
9. Cooper's 1997 classic study on 1182 TMD patients
10. Baragar FA, Osborn JW: *A model relating patterns of human jaw movements to biomechanical constraints*. *J Biomech*. 1984;17(10):757-67.
11. Osborn, JW: *A model to describe how ligaments may control symmetrical jaw opening movements in man*. *J Oral Rehabil*. 1993 Nov;20(6):585-604.
12. Osborn JW: *Internal derangement and the accessory ligaments around the temporomandibular joint*. *J Oral Rehabil*. 1995 Oct;22(10):731-40.
13. Yatabe M, Zwijnenburg A, Megens CC, Jaeije M: *Movements of the mandible condyle kinematic center during jaw opening and closing*. *J Dent Res*. 1997 Feb; 76(2):714-9.
14. Jankelson RR: *Neuromuscular Diagnosis and Treatment*. Ishiyaku Euro America, Inc, St Louis, Missouri.
15. Chan, CA: *Mastering Scan 4/5 with the Modified CHAN SCAN (Optimizing the NM Trajectory)*, Data Collection and Scan Interpretation manual, Chapter 5, Las Vegas Institute for Advanced Dental Studies, December 2002.
16. McNamara JA, Hinton RJ, Hoffman DL: *Histological analysis of the temporomandibular joint adaptation to protrusive function in young adult rhesus monkeys, macaca mulatta*. *AmJOrthod* 82; 288, 1982,
17. Schneidermand ED and Carlson DS: *Cephalometric analysis of condylar adaptation to altered mandibular position in adult rhesus monkeys, macaca mulatta*. *ArcOralBiol*. 30-49, 1985.
18. Rufs and Pancherez H: *TMJ growth adaptation in Herbst treatment: a prospective MRI and ceph study*. *EuroJ of Orthod*. Volume 20, issue #4 Aug 1998.

19. Chan, CA: *Neuromuscular Occlusion – The Zone of Neutrality*, LVI Dental Vision, May/June Vol. 10, Number 3.
20. Myotronics-Noromed, Inc., K7 Kineseograph K6-i/K7 and the Myomonitor J4/J5, Tukwila, Washington.
21. Hiraba, K, Hibino, K, Hiranuma, K, and Negoro, T: *EMG activities of two heads of the human lateral pterygoid muscle in relation to mandibular condyle movement and biting forces*. *J Neurophysiol* 83:2120-2137, 2000.
22. Jennings, D.: *Speech as a Diagnostic Criteria for the Identification of Craniomandibular Dysfunction and for Evaluating Treatment Progress*. *Anthology of Craniomandibular Orthopedics: Volume III, ICCMO*, 325-330.
23. Chan, CA: *Advanced scan interpretation course manual*, Las Vegas Institute for Advanced Dental Studies, 2003.
24. *Luschei ES: Neural mechanisms of mandibular control: mastication and voluntary biting. In: Brooks VB, Handbook of Physiology, Section I: The Nervous System, Vol. 2, Motor control, Bethesda: American Physiological Society: 1981;1237-1274.*
25. *Kaas JH: Plasticity of sensory and motor maps in adult mammals. Annu Rev Neurosci 1992;14:137-167.*
26. Chan, CA and Wade, W: *First Study - A Clinical Comparative Study of the Classic Scan 4/5 versus the Optimized (Chan Scan)*, 53 candidates (29 males, 25 female), June 2003. *Second clinical study - CHAN SCAN STUDY #2* comprised of 20 NM Technicians, (14 males, 6 females). Las Vegas Institute for Advance Dental Studies, Las Vegas, Nevada, March 11, 2004.